

Fat Myringoplasty



Adel Abdel-Baki Abdallah¹, Mostafa Sayed Hammad¹, Ahmad Adel Sadeq¹, Zaki Mohamed Zaki²,
Heballa Ali Ahmed Ali¹ Mostafa Talaat Abd-El Hakeem¹

¹Otorhinolaryngology Department, Faculty of Medicine, Minia University- Egypt

²Clinical Pathology Department, Faculty of Medicine, Minia University- Egypt

Abstract— Purpose: To assess the ability of topical use of autologous platelet rich plasma (PRP) to improve success rate of myringoplasty. **Patients and Methods:** This investigation was led to the ENT Department at Minia University Hospital and included 30 patients with different sizes, dry, central tympanic membrane perforation, attending the E.N.T.outpatient clinic. Half of them had myringoplasty from fat graft (group A), and others were fatty graft with PRP (group B). **Results:** The graft was taken in 13 patients (86.7%) in group A, and in 14 patients (93.3%) in group B. Healing time was shorter in group B (2 months) than in group A (3 months). There was insignificant different between the two graft types in hearing gain, but in each graft type there was significant decrease in the mean ABG postoperatively. **Conclusion:** Effective autologousPRP application during myringoplasty has favorable healing results in small, medium sized and large central perforations.

Keywords: Myringoplasty - Platelet Rich Plasma - tympanic membrane - fat graft - Chronic Suppurative Otitis Media.

Introduction

The goal of myringoplasty is to reconstruct the tympanic membrane and the sound conducting mechanism. Fat unite myringoplasty has been first depicted in 1962 by Ringenberg 1 as a basic procedure for fixing of TM holes with detailed achievement rates differing somewhere in the range of 76% and 92%. The fat of the ear lobule was discovered to be more minimized and contain more stringy tissue. By bridging the void, it offers scaffolding for the development of the tympanic endothelium and nasal mucosa. It is accessible conveniently in the same place of surgery.

PRP is a easy procedure for extracting high - grain autologous growth factors that is noninvasive. As it is ready from autologous blood, PRP is affordable than signaling pathways and holds no risk of transmission infection. In the first human PRP application during myringoplasty,El-Anwar Et al.2 demonstrated a positive PRP impact on recuperating with ideal outcomes in huge TM hole. The study discusses improvement of success rates in fat myringoplasty after application of topical PRP and acceleration of healing. 2.

Patients and Methods: The study participants were recruited from patients with perforated drum attending outpatient clinic, Otorhinolaryngology Department, Minia University Hospital, during the period from January 2018 to October 2019. 30 patients having chronic suppurative otitis media (safe type) or traumatic ear perforation persisting for more than 6 months, both with dry ears for at least 3 months were included. All patients participated voluntarily in our study and were consented for the procedures. The patients were divided into two groups, 15 patients in each. 1st group underwent fat graft myringoplasty, and 2nd group with PRP added to fat graft.

All patients were subjected to full history taking, general and local examination, including otoscopic and endoscopic ear examination with full audiometric and Eustachian tube function testing. The sizes of TM perforations were also recorded (endoscopically) and classified according to the Saliba, 2008³ into:

Perforation	Size in percent	TM quadrant affected	
Small	Less than 25%	Less than one Q size	
Medium	More than 25% Less than 50%	More than 1 Q size and Less than 2 Q size	
Large	More than 50% Not total	More than 2 Q size and Not total	
Total	100% or total	Completely 4 Q size	

Figure (1): Perforation size subdivision based on the four tympanic membrane quadrant size (Saliba's subdivision). Q=quadrant

2.1. Preparation of autologous PRP: During acceptance of sedation and initial steps of medical procedure, 10 ml of fringe venous blood was drawn from the patient with a 10 ml needle to evade aggravation and harm of the platelets; at that point gathered blood was kept in a 5 ml plain vacuum cylinders, and afterward the cylinders were quickly centrifuged utilizing a tabletop rotator machine lastly the temperature of the centrifugation was kept at 20° C to 24°C.

So blood was isolated out into the three layers attributable to the thickness of its inward substance: the base layer comprises of red platelets, the center layer contains PRP (about 1.5 ml3), which is made out of platelets and white platelets (WBCs; buffy coat) that could be handily gotten and the top layer contains platelet helpless plasma. The PRP layer was taken out at the season of utilization.

2.2. **Method:** The ear flap was invaded utilizing 2% lidocaine with 1:100,000 adrenaline to forestall dying. A 5 mm entry point was made at the average surface of the tip of the earprojection.

The skin was subverted and a measure of fat has twice as the size of the hole was collected in one piece and was placed in a clean saline arrangement. The cut was shot by a couple of 3/0 silk stitches. The whole procedure was performed transcanally, with no external incision. The margins of the perforation were de-epithelialized circumferentially with sharp curved needle, under vision of 0°, 2.7mm × 9 cm rigid endoscope connected to single chip STORZ camera. In case of medium and wide resection, the Gelfoam fragments were placed in the central ear by means of a drilling to protect the fat graft.

The fat device was then integrated through the gap, swelling by the hole, as an hourglass-shaped extension. Give sure that the fat hits all sides of the hole with some fat over the gap for the definitive end of the hole..Gelfoam was embedded on the sidelong surface of the join and tympanic film leftover in the outer hear-able trench (EAC).

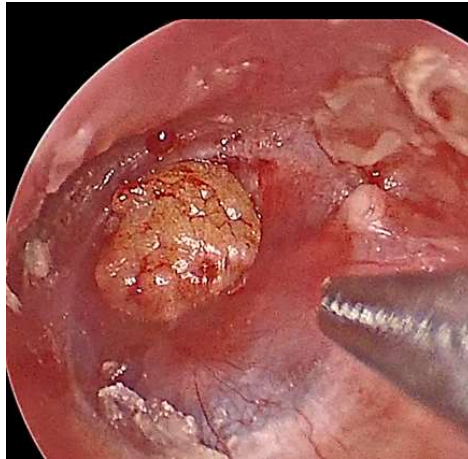

Figure (2): Fat join to set up In bunch A: No PRP is added to the united. In group B: Before and after placing and adjusting the graft in its place, PRP is applied on fat graft and gel foam in the middle ear and EAC.

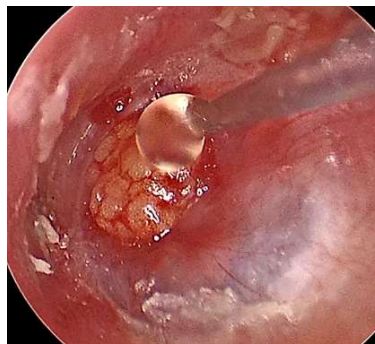

Figure (3): PRP on fat graft The outer ear is packed with fragments of gelfoam in both classes, and the outer ear opening is covered with a merocel ear pack. The coating was left for 1 week over the treated ear. 2.3.-2.3. Preoperative follow-up: systemic antibiotics, decongestant and non-steroidal anti-inflammatory agents of a wide spectrum were identified for 1 week. After 1 week, the package and stitches were removed, and antibiotics ear drops were recommended for 2 weeks after the outer ear band was removed. The patients were monitored for 1 month at time points and for 3 months at months follow-up.

The patients in this investigation were assessed based on postoperative unite taking, hearing improvement, and intricacies. The effective conclusion of the hole was characterized as a flawless TM at 3 months postoperatively. Accomplishment as far as the hearing was characterized as an improvement of 10 dB or more prominent at 3 months.

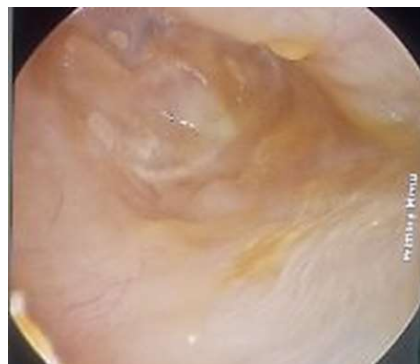

Figure (4): Healed TM a month and a half postoperatively 3. Statistical analysis: The gathered information was coded, arranged, and factually broke down utilizing theSPSS program (Statistical Package for Social Sciences) programming form 25.Descriptive statistics were done for parametric

(normally distributed) quantitative data by mean, Standard deviation (SD) and minimum and maximum of range, for non-parametric (not normally distributed) quantitative data by median and interquartile range (IQR), while they were done for categorical data by number and percentage. Analyses were done for parametric quantitative data between two groups using Independent samples T test.

Analyses were done for Qualitative data between groups using Chi square test The level of significance was taken at (P value < 0.05) 3.1. Results: The graft success was achieved in 27 patients, 13 patients (86.7%) in group A, and in 14 patients (93.3%) in group B. No lateralization or medialization was seen in the successful cases. The demographic characteristics of both groups with no statistical difference between both groups in age and sex are shown in Table 1. In this regard, in group A, the mean age of the patients was 34.5±10.3 years with predominance of males representing (53.3%). In group B, the mean age of the patients was 31.6±9.3 years with females representing (53.3%)

Table (1): Comparison between the two groups regarding demographic data.

Demographic data		Type of graft		P value
		FAT	FAT+PRP	
		N=15	N=15	
Age	Range	(19-50)	(18-47)	0.421
	Mean ±	34.5±10.3	31.6±9.3	
	SD			
Sex	Male	8(53.3%)	7(46.7%)	0.715
	Female	7(46.7%)	8(53.3%)	

- Independent samples T test for parametric quantitative data between the two groups
- Chi square test for qualitative data between the two groups
- Significant level at P value < 0.05

As regarding pre- and postoperative mean ABG and hearing gain, there was insignificant difference between the two graft types, but in each graft type there was significant decrease in the mean ABG postoperatively.

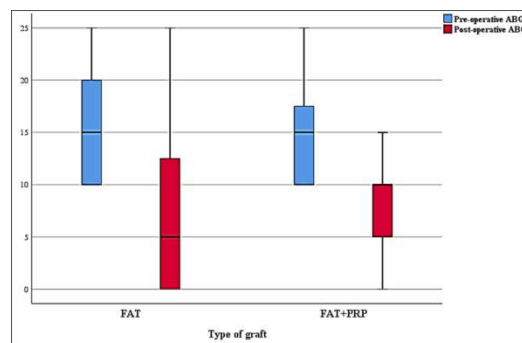


Figure (5): Relation between preoperative and postoperative ABG and graft type.

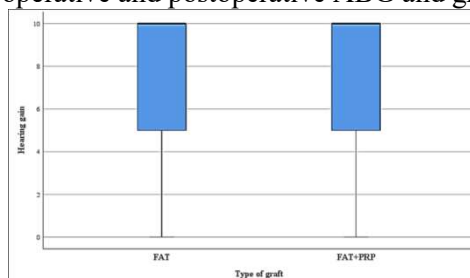


Figure (6): Relation between hearing gain and type of graft. As regarding healing, there was insignificant difference between the two graft types, but FAT showed significant increase in time to heal compared to

FAT+PRP as shown in table (2).

Table (2): Healing and time to heal in relation to type of graft

		Type of graft		P value
		FAT	FAT+PRP	
		N=15	N=15	
Healing	Not healed	2(13.3%)	1(6.7%)	1
	Healed	13(86.7%)	14(93.3%)	
Time to heal	<i>Median</i>	3	2	0.035*
	<i>IQR</i>	(2-4)	(2-3)	

- Fisher’s Exact test for qualitative data between the two groups
- *Significant level at P value < 0.05

Discussion:

Myringoplasty is a reconstructive activity of the TM performed to forestall intermittent ear release and to improve hearing impedance brought about by TM perforation⁴. Hagemann and Hausler⁵ (2003) noted the conclusion of a hole in 91% of cases and a hearing increase of 5-10 db. Chalishazar (2005) The conclusion of TM hole was seen in 89 percent of cases of fat entering myringoplasty. Cases of perforation of the tympanic membrane covering less than 25 percent of the total region were selected. A study of 342 children who experienced fat graft myringoplasty and obtained safety devices in 92 percent of the ears was identified by Mitchel et al.⁷ (1997).

Roe Landsberg et al.⁸ (2006) conducted 38 perforations of fat graft myringoplasty and observed 81.6 percent effective closure. They mentioned Signi, too? No increase in the criterion for speech reception (18.5 ± 7.7 dB vs. 23.5 ± 8dB). The mending of the hole is finished inside 2-3 months in the vast majority of the cases. Recuperating happens by epithelialisation over the platform of the fat unite. Yet, fat join itself sets aside longer effort for complete resumption to happen. The only graft material on which Ringenberg⁹ had sufficient experience to compare the results with the fat is temporalis fascia. Fat has a lower take rate (86%) compared to fascia (95%).

The long-term studies, however, demonstrate that, in 90% of fat graft cases, the drumhead is thin and freely mobile. Hearing improvement occurs in 90% of patients. Blunting of the anterior sulcus or lateralization of the graft has not occurred. Sergi B.¹⁰ et al noticed that the use of autogenous fat grafts in head and neck surgery has been associated with some unpredictability. In many applications, noteworthy resorption of the relocated fat can be normal, and it ought to be made up for likewise by starting overcorrection.

PRP as a transporter of development factors quickens endothelial, epithelial, and epidermal recovery, invigorates angiogenesis, improves collagen combination and delicate tissue recuperating, diminishes dermal scarring, and elevates the hemostatic reaction to injury. The autologous PRP is basic and simple to be set up with no revealed results. (Smith RG, et al., 2007)¹¹ In this study, the graft take rate was excellent in cases used PRP (93.3%) with significant higher take rate than without PRP use (which was 86.7%). El Anwar¹², et al.,2015 saw that the join take rate was flawless in all cases (100% achievement rate) with the utilization of PRP with inclination than without PRP use with no revealed difficulty including disease that was accounted for to be fundamentally higher in control gathering. Our investigation additionally concurs with crafted by Nakamura¹³ and associates. They contrasted fat unite mending and without PRP by makingsubcutaneous dorsal pockets in their experimental investigation on rodents to show the impacts of PRP on fat joinresorption.

They made a 90% progress rate in the rodents which went through fat attachment myringoplasty in addition to PRP. These outcomes demonstrate the part of autologous PRP in upgrading the recuperating of TM even in an enormous hole. No effect of PRP use on hearing gain in graft take cases because hearing gain related to closure of TM. Ends: In our investigation, we found that autologous PRP application quickens TM conclusion following fat attachment myringoplasty, and forestalls unite uprooting.

It likewise diminishes season of mending, exceptionally effective and fruitful with no announced complexity. The utilization of autologous PRP has preferences as it is an autogenous material, consistently accessible, less exorbitant, and has no dangers of sensitivity, poisonousness, or unite dismissal. We didn't locate a noteworthy distinction between the 2 gatherings in hearing increase. We recommend using PRP for tympanic membrane reconstruction.

Conflict of interest: None Funding Sources: This study was supported by personal funds and funds from Minia University. Ethical approval: All procedures performed in this study followed the 1964 Helsinki declaration and its later amendments and was approved by the local research ethics committee at Minia Faculty of Medicine. Informed consent was obtained from all the study participants.

References

- [1] Ringenberg JC. (1962): Fat graft tympanoplasty Laryngoscope; 72:188-92.
- [2] El-Anwar MW, El-Ahl MA, Zidan AA, Yacoup MA.(2015): Topical use of autologous platelet rich plasma in myringoplasty. *AurisNasus Larynx*; 42(5):365-8.
- [3] Saliba I. (2008): Hyaluronic acid fat graft myringoplasty: how we do it. *ClinOtolaryngol*; 33(6):610-614.
- [4] Al-Khtoum N, Hiari MA. Myringoplasty in children (2009): retrospective analysis of 35 cases. *Braz J Otorhinolaryngol*; 75:371-4.
- [5] Hagemann M, Hausler R. (2003): Tympanoplasty with adipose tissue. *Laryngorhinootologie* 82(6):393-6.
- [6] Chalishazar U. (2005): Fat plug myringoplasty. *Indian J Otolaryngol Head Neck Surg* 57:43-4.
- [7] Mitchell RB, Pereira KD, Lazar RH. (1997): Fat graft myringoplasty in children-a safe and successful day-stay procedure. *J LaryngolOtol* 111:106-8.
- [8] Roe L, Gadi F, Ari D, Eli B, Gilead B.(2006): Fat join myringoplasty: consequences of a long haul development. *J Otolaryngol* 35(1):44-7.
- [9] Ringenberg J. (1978): Closure of tympanic layer hole by the utilization of fat. *Laryngoscope*; 88:982-93.
- [10] Sergi B, Galli J, Corso E, Parrilla C, Paludetti G. (2011): Overlay versus underlay myringoplasty: report of results thinking about conclusion of hole and hearing capacity ;*ActaOtorhinolaryngol Ital.*; 31(6):366-371
- [11] Smith RG, Gassmann CJ, Campbell MS. (2007): Platelet-rich plasma: properties and clinical applications. *J Lanc Gen Hosp*; 2:73-7.
- [12] El-Anwar MW, El-Ahl MA, Zidan AA, Yacoup MA.(2015): Topical use of autologous platelet rich plasma in myringoplasty. *AurisNasus Larynx*; 42(5):365-8.
- [13] Nakamura S, Ishiara M, Takikawa M, Murakami K, Kishimoto S.(2010): Platelet rich plasma (PRP) promotes survival of fat-grafts in rats. *Ann PlastSurg*; 65:101-106.



This work is licensed under a Creative Commons Attribution Non-Commercial 4.0 International License