

THE EFFECT OF SCOLIOSIS CORRECTION SURGERY ON QUALITY OF LIFE OF ADOLESCENT IDIOPATHIC SCOLIOSIS (AIS) PATIENTS

Naufal Ranadi Firas^{1,2}, Feby Andika Firdausi^{1,2}, Lukas Widhiyanto^{1,2}



¹Department of Orthopaedic and Traumatology, Faculty of Medicine, Airlangga University, Surabaya, Indonesia

²Dr. Soetomo General-Academic Hospital, Surabaya, Indonesia

Abstract— Surgery in scoliosis patients can affect postoperative quality of life, especially in adolescents (AIS). Early detection of AIS and proper management are the keys to a satisfactory outcome. This study aims to assess the clinical condition or quality of life of postoperative patients and improvement of the Cobb angle degree in AIS patients at Dr. Soetomo Hospital. This research is a cross-sectional study. Patient data obtained from medical records include age, gender, and year of operation. Radiological data obtained by measuring the difference in Cobb angle pre and postoperatively. Clinical outcome data were obtained from the SRS (Scoliosis Research Society) Questionnaire Version 30. There were 22 patients in this study, consisting of 17 female patients (77.2%) and 5 male patients (22.8%). The average value of the correction angle of the Cobb angle is $(30.73^{\circ} \pm 15.25^{\circ})$. Based on the results of the calculation of the SRS-30 questionnaire, the mean function value is 3.94 ± 0.24 , the mean pain value is 3.96 ± 0.42 , the mean self-image value is 3.29 ± 0.27 , the average mental health value is 3.37 ± 0.49 , and the average value of the level of satisfaction with operating result is 3.28 ± 0.28 . From this research, found a positive effect on aspects of postoperative quality of life in AIS patients.

KEYWORDS: scoliosis, adolescent, surgery, spine.

1. Introduction

Adolescence Idiopathic Scoliosis (AIS) is the most common type of idiopathic scoliosis, this condition begins in early puberty, affects 1-4% of adolescents and more common in women than men. The clinical manifestations of AIS can range from asymptomatic or minor complaints such as back pain, to cardiopulmonary symptoms and neurological disorders[1]. Spinal deformities in scoliosis patients can reduce a person's self-confidence, especially in their teens. This deformity significantly deteriorates the ability of independently performing activities of daily living and contribution in social activities. The appearance of the patient especially in females, affects the mental health, self confidence, and self-image making them avoid participation in groups of school and other public societies [2].

Management of AIS can be conservative with observation and braces or surgery. Operative therapy is carried out with internal fixation[3]. The goal of surgery is to correct the deformity, maintain sagittal balance, improve lung function, minimize morbidity or pain, maximize postoperative function, and improve or at least not injure the function of the lumbar spine[4,5]. Improvement in patients can be evaluated in various ways, both radiologically visible improvement by comparing the Cobb angle before and after correction, or by using a questionnaire. One of the questionnaires that can be used is the SRS-30 (Scoliosis Research Society-30 item) which is a special instrument to measure health-related quality of life in scoliosis patients who have undergone surgery or have never had surgery. The purpose of this questionnaire was to evaluate pain, function, self-image, mental health and satisfaction with the management of scoliosis patients and to compare surgical and conservative treatment[6].

This study was conducted with the aim of knowing the evaluation of Scoliosis Correction surgery in patients with AIS, assessed from the improvement of the Cobb Angle degree in patients, along with the evaluation of the clinical condition or quality of life of postoperative patients using the SRS-30 questionnaire. Thus, it is hoped that the results will be obtained in the form of how effective the Scoliosis Correction surgery is in patients with AIS.

2. Methods

This study is a cross-sectional study that has been approved by the Ethic Committee of Dr. Soetomo General Academic Hospital Ref. No.0037/KEPK/VIII/2020. The inclusion criteria in this study included 1) Patients with a diagnosis of Adolescent Idiopathic Scoliosis without other abnormalities, 2) Follow-up was carried out at least 1 year after surgery, and 3) Patients were willing to participate in this study. All operations were performed by a single spinal surgeon and used the same surgical instruments, namely the pedicle screw and rod. All operations were performed with the posterior instrumentation technique.

Patients data were obtained from medical records include age, gender, and year of surgery. Radiological data obtained by measuring the difference in Cobb angle pre and postoperatively. Cobb angle was measured the sum of upper and lower end vertebra tilt angles from the anterior-posterior view on the pre-and post-operative radiographs using a goniometer. Clinical outcome data were obtained from the SRS (Scoliosis Research Society) Questionnaire Version 30. Patients were asked to complete the SRS-30 questionnaire. This questionnaire consists of five domains, including function, pain, self-image, mental health, and satisfaction with surgery. Value ranges from 1 (worst outcome) to 5 (best outcome). The value of each domain is obtained from the sum of the scores for each question from the calculated domain divided by the number of questions in that domain.

We analyzed the statistics using SPSS Version 21 to find the mean and standard deviation of each research variable.

3. Results

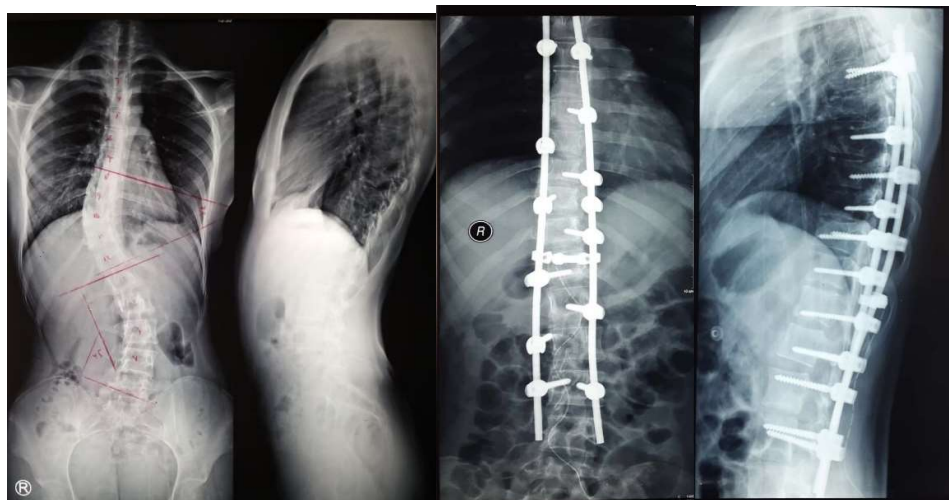
There were 22 patients in this study, consisting of 17 female patients (77.2%) and 5 male patients (22.8%), with an age range at the time of surgery between the ages of 10 – 18 years (15.0 ± 2.3 years) and the age range at the time of follow-up was carried out between the ages of 13 – 23 years (19.0 ± 2.5 years) with the longest follow-up was 8 years since surgery. The mean value of Cobb angle before surgery was ($65.86^\circ \pm 16.12^\circ$). The mean value of the correction angle of the Cobb angle is ($30.73^\circ \pm 15.25^\circ$) and the average value of the Cobb angle after surgery is ($26.86^\circ \pm 5.79^\circ$). No patient underwent surgery twice.

Based on the results of the calculation of the SRS-30 questionnaire, the mean function value is 3.94 ± 0.24 , the mean pain value is 3.96 ± 0.42 , the mean self-image value is 3.29 ± 0.27 , the average mental health value is 3.37 ± 0.49 , and the average value of the level of satisfaction with operating result is 3.28 ± 0.28 . In general, we obtained good scores on pain and function scoring (SRS-30) while lower scores on self-image, mental health, and postoperative satisfaction (SRS-30) scores were obtained. The characteristics of the research subjects can be seen in table 1.

Table 1. Radiological data, clinical pain, function, level of confidence, mental health, and level of satisfaction with surgery results (SRS-30) in Adolescent Idiopathic Scoliosis patients.

Patients	Sex	Age at surgery	Cobb angle ($^\circ$)			SRS-30			
			Pre-	Post-	Correction	Function	Pain	Self-	Mental

		(year)	op	op				<i>image</i>	Health	
1	F	12	62	21	41	4.14	4.17	3.67	4.2	3.33
2	F	18	99	32	67	4	3.83	3.11	3.2	3
3	F	16	49	28	21	4	4.33	3.11	3	3
4	M	16	70	21	49	4	4.5	3.67	4	3
5	F	15	60	28	32	3.86	3	3	3	3.33
6	M	18	73	37	36	4.14	3.5	3.33	2.6	4
7	F	14	48	21	27	4.28	4.33	3.55	3.6	3
8	F	16	88	60	28	3.86	3.67	3.11	3.2	3.33
9	F	10	66	31	35	4.14	4.17	3.22	3.2	3.33
10	M	16	50	26	24	3.29	4	3	3.4	3.67
11	F	15	32	19	13	4.14	4.5	3.55	4.2	3.33
12	F	18	65	57	8	4.14	4	3.78	3.8	3.33
13	F	18	62	48	14	4	4	3.11	3.2	3
14	F	14	69	48	21	3	3.83	3	2.8	3.33
15	F	16	44	28	16	4.14	4.33	3.22	3.4	3.33
16	F	16	59	39	20	3.71	2.83	3.33	2.8	4
17	F	17	45	12	33	4.14	4.67	3.78	3.8	3
18	M	15	70	18	52	3.85	4.33	3.44	3.4	3.33
19	F	12	80	30	50	4	3.5	3.11	3.4	3
20	M	18	85	36	49	4	3.83	2.78	3.2	3
21	F	13	45	20	25	3.71	3.16	3.22	3.4	3.33
22	F	12	50	34	16	4.14	4.67	3.11	3	3



A

B

Figure 1. Patient number 17 (female patient, surgery at 17 years old). The radiographs showed that the Cobb angle (1A) pre-operative (45°) and (1B) post-operative (12°) difference was 33°

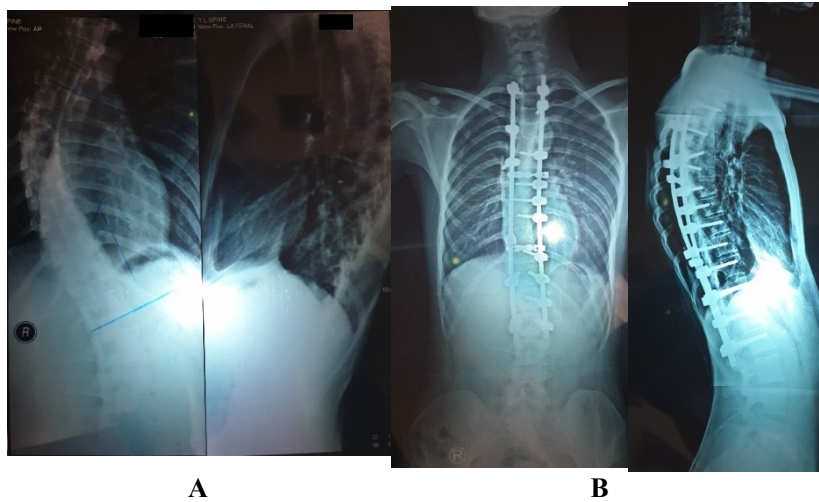


Figure 2. Patient number 10 (male patient, surgery at 16 years old). The radiographs showed that the Cobb angle (2A) pre-operative (50°) and (2B) post-operative (26°) difference was 24° .

4. Discussion

In this study, the patient's average age was 16 years with a female:male ratio ratio of 2.25:1 which is in concordance with other studies in term of female:male ratio on the Cobb Angle $>10^\circ$ curve was 2.7 : 1, the Cobb Angle $>20^\circ$ curve is 4.5:1. While the Cobb Angle $>40^\circ$ curve, the female:male ratio is 8.1:1[7]. In other studies, it is also stated that the prevalence of scoliosis according to gender twice as many women as men at all ages[8]. From the results of the Cobb angle correction in this study, the results were not much different from other studies, where in other studies the degree of Cobb angle correction was $30 \pm 19^\circ$ [9]. On evaluation after 2 years of surgery, the mean reduction of the cobb angle was 26.6° or 40.7% of the preoperative curve in 2129 patients[10].

Previous study stated the impact of scoliosis on the quality of life of adolescents by comparing the SRS-22 questionnaire scores of adolescents with scoliosis with scores from the same questionnaire completed by adolescents without scoliosis. 81% of the published series showed that the adolescents with scoliosis registered a reduction in the pain score, even though only 5% of the series was this difference clinically relevant. On the other hand, self-image decreased in 91% of the series, of which 73% were clinically relevant reductions. In addition, neither mental health nor function showed clinically important differences[11].

Adolescence is a relatively sensitive age period in term of psychological development, the physical difference from their peers caused by scoliosis can affect the level of self-confidence in their social life and may take effect of the patient's psychological condition and social pressure[12]. Preoperative physical characteristics, psychological difficulties, and unrealistic expectations regarding postoperative cosmesis are associated with patient neutrality or dissatisfaction[13]. Eventually patients may experience significant psychological distress, body image problems, and other quality of life problems[14].

This situation most probably caused by their own expectation and the negative effect of scoliosis correction surgery with the functional goals to reduce future pain levels and disability in adulthood[15]. Other study stated patients treated surgically were found to have a better self-image than patients treated with a brace, the negative effect that the deformity exerts on perceived self-image but the overall quality of life was improved by a reduction in the magnitude of the curve[16]. Other study also stated the surgical correction of adolescent idiopathic scoliosis can lead not only to curve correction, but also to an increase self-esteem and life satisfaction[17]. This data suggested that although surgery can lead to clinically important improvement in patient self-image, surgeons and patients should be aware of the limited studies to guarantee satisfying self-image after surgery and patients should be involved more in the decision making process[11]

In another study, it was stated that from the results of postoperative scoliosis evaluation using the SRS-30 questionnaire, the average value of the function assessment was 3.83 ± 0.87 , pain assessment 4.09 ± 0.78 , self-image assessment 3.17 ± 0.81 , mental health assessment 3.08 ± 0.98 , and satisfaction level assessment with surgery of 1.52 ± 0.53 [11]. This study more or less shows the same SRS-30 scoring results as Yilmaz and Kuru's study, but a very significant difference occurs in the level of satisfaction, where the postoperative satisfaction level in this study is much better than Yilmaz and Kuru's study[18].

This research supports the need for future studies to fully assess the impact of scoliosis surgery on various aspects (clinical, radiological, and quality of life) of AIS patients in Indonesia. Recent research similar to this study and covering a larger number of samples and taken from several tertiary health centers in Indonesia needs to be done. Future studies also need to carry out a more in-depth analysis of risk factors and long-term complications that can occur after surgery.

CONCLUSION

The overall score of the assessment of the quality of life of postoperative scoliosis patients from this study showed good results. This shows that there is a positive influence on the aspects of postoperative quality of life in AIS patients.

REFERENCES

- [1] Cheng, J. C. *et al.* (2015) 'Adolescent idiopathic scoliosis', *Nature Reviews Disease Primers*, 1. doi: 10.1038/nrdp.2015.30.
- [2] Misterska E, Glowacki M, Harasymczuk J. Personality characteristics of females with adolescent idiopathic scoliosis after brace or surgical treatment compared to healthy controls. *Med Sci Monit.* 2010;16(12):CR606-15.
- [3] Yaman, O. and Dalbayrak, S. (2014) 'Idiopathic scoliosis', *Turkish Neurosurgery*, 24(5), pp. 646–657. doi: 10.5137/1019-5149.JTN.8838-13.0.
- [4] Konieczny, M. R., Senyurt, H. and Krauspe, R. (2013) 'Epidemiology of adolescent idiopathic scoliosis', *Journal of Children's Orthopaedics*, 7(1), pp. 3–9. doi: 10.1007/s11832-012-0457-4.
- [5] Victoria Gacitúa, M. (2016) 'Adolescent idiopathic scoliosis', *Archivos Argentinos de Pediatría*, 114(6), pp. 585–594. doi: 10.5546/aap.2016.585.
- [6] Yilmaz, H. and Kuru, T. (2012) 'A comparison of results of SRS-30 questionnaire in scoliosis patients treated surgically or conservatively', *Scoliosis*, 7(S1), pp. 1–2. doi: 10.1186/1748-7161-7-s1-p15.
- [7] Luk, K. D. K. *et al.* (2010) 'Clinical Effectiveness of School Screening for Adolescent

- Idiopathic Scoliosis', *Spine*, 35(17), pp. 1607–1614. doi: 10.1097/brs.0b013e3181c7cb8c.
- [8] Nery, L. S. *et al.* (2010) 'Prevalence of scoliosis among school students in a town in southern Brazil', *Sao Paulo Medical Journal*, 128(2), pp. 69–73.
- [9] Kim, Y.-J. *et al.* (2006) 'P77. Comparative analysis of pedicle screw versus hybrid instrumentation in posterior spinal fusion of adolescent idiopathic scoliosis: a match cohort analysis', *The Spine Journal*, 4(5), p. S85. doi: 10.1016/j.spinee.2004.05.171.
- [10] Yadla, S. *et al.* (2010) 'Adult scoliosis surgery outcomes: a systematic review', *Neurosurgical focus*, 28(3), p. E3.
- [11] Rushton PRP, Grevitt MP. Comparison of untreated adolescent idiopathic scoliosis with normal controls: A review and statistical analysis of the literature. *Spine*. 2013;38:778–785.
- [12] Danielsson AJ, Wiklund I, Pehrsson K, Alf L, Nachemson. Health-related quality of life in patients with adolescent idiopathic scoliosis : a matched follow-up at least 20 years after treatment with brace or surgery. *Eur Spine J* (2001) 10:278-288.
- [13] Ameri E, Behtash H, Mobini B, Bouzari B, Tari V. Patient satisfaction after scoliosis surgery. *Medical Journal of The Islamic Republic of Iran (MJIRI)*. 2008 Feb 10;21(4):177-84.
- [14] Tones M, Moss N, Polly DW Jr. A review of quality of life and psychosocial issues in scoliosis. *Spine*. 2006;31:3027–3038.
- [15] Bridwell KH, Shufflebarger HL, Lenke LG, *et al.* Parents' and patients' preferences and concerns in idiopathic adolescent scoliosis: a cross-sectional preoperative analysis. *Spine*. 2000;25:2392–2399.
- [16] Carrasco MI, Ruiz MC. Perceived self-image in adolescent idiopathic scoliosis: an integrative review of the literature. *Revista da Escola de Enfermagem da USP*. 2014;48:748-57.
- [17] Zhang J, He D, Gao J, Yu X, Sun H, Chen Z, Li M. Changes in life satisfaction and self-esteem in patients with adolescent idiopathic scoliosis with and without surgical intervention. *Spine*. 2011 Apr 20;36(9):741-5.
- [18] Yilmaz, H. and Kuru, T. (2012) 'A comparison of results of SRS-30 questionnaire in scoliosis patients treated surgically or conservatively', *Scoliosis*, 7(S1), pp. 1–2. doi: 10.1186/1748-7161-7-s1-p15.



This work is licensed under a Creative Commons Attribution Non-Commercial 4.0 International License.